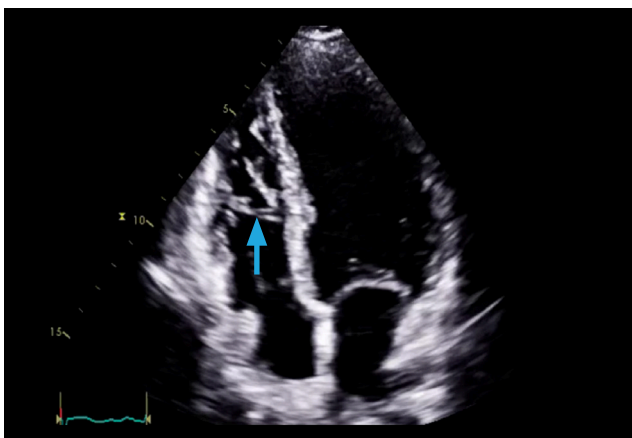


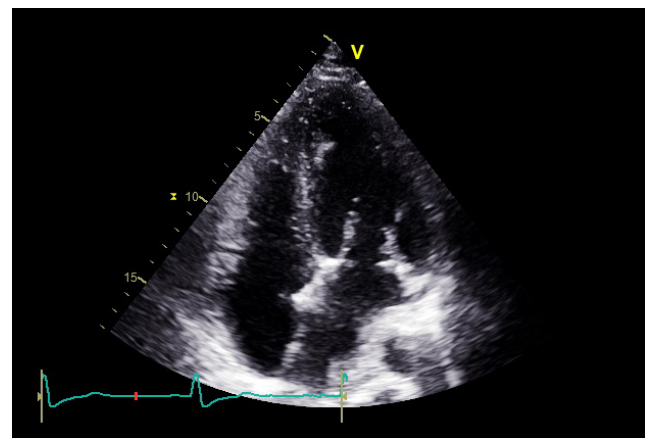
OTHER USES OF TTE

Recognizing imitation masses

- A Chiari net is a normal finding in the right atrium.
- A eustachian valve may be seen at the mouth of the IVC. It can be thin or thick and fixed or mobile.
- The right ventricle is normally trabeculated with a moderator band towards the apex.
- Generalized thickening of cardiac structures can occur with age.



Moderator band



Thickened mitral valve annulus and atrial septum